

# **BASICS IN DERMATOLOGY**

**ERNESTO GONZALEZ, M.D.**  
**PROFESSOR OF DERMATOLOGY**  
**HARVARD MEDICAL SCHOOL**

# BASICS IN DERMATOLOGY

## **DISCLAIMER**

**NO**

**CONFLICT OF INTERESTS**

**OR**

**FINANCIAL SUPPORT**

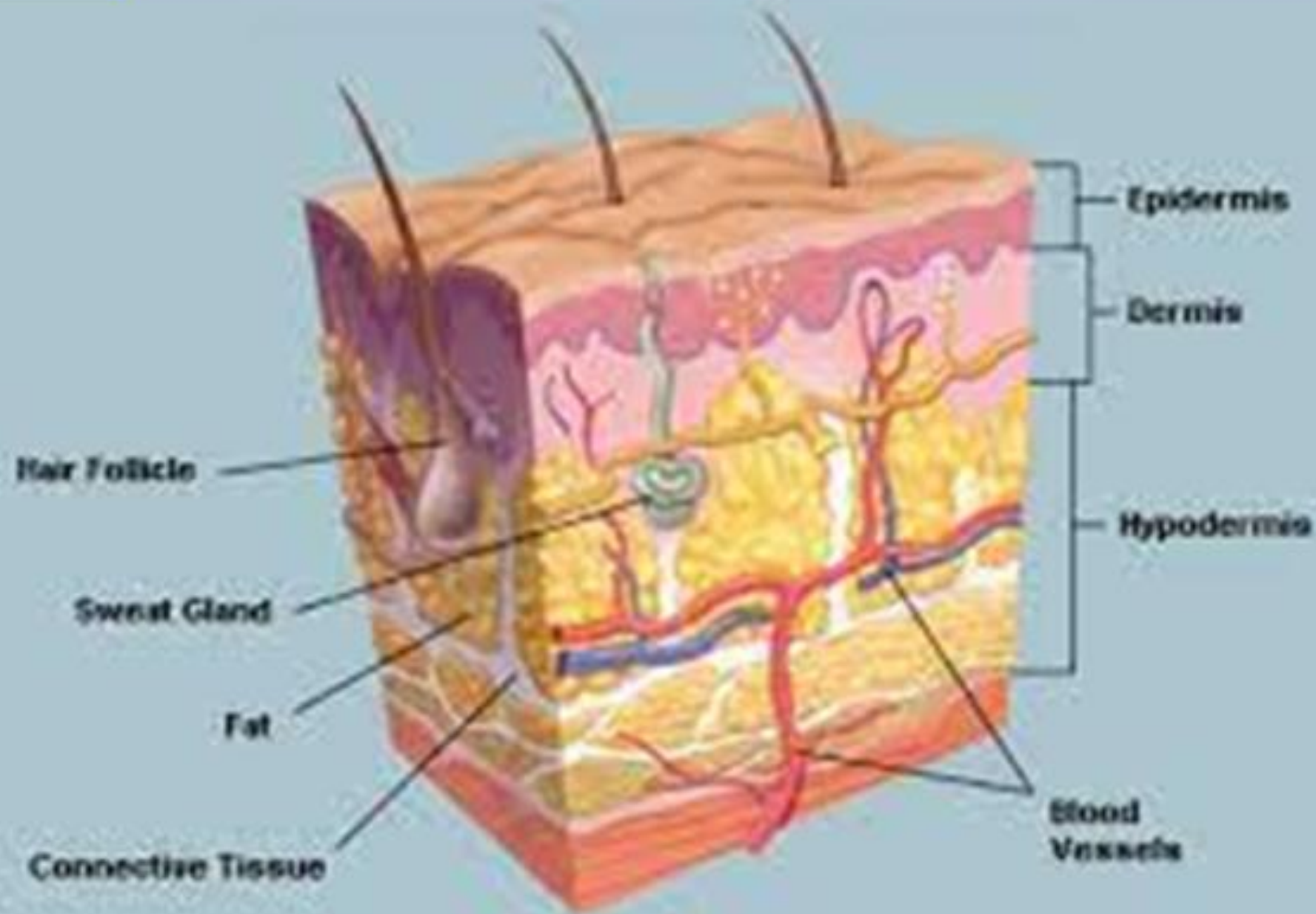
# PHYSICAL DIAGNOSIS

- HISTORY
- PHYSICAL EXAMINATION
  - VISUAL
  - PALPATION
- INTUITION: PATTERN RECOGNITION

# PHYSICAL EXAMINATION

## CARDINAL FEATURES

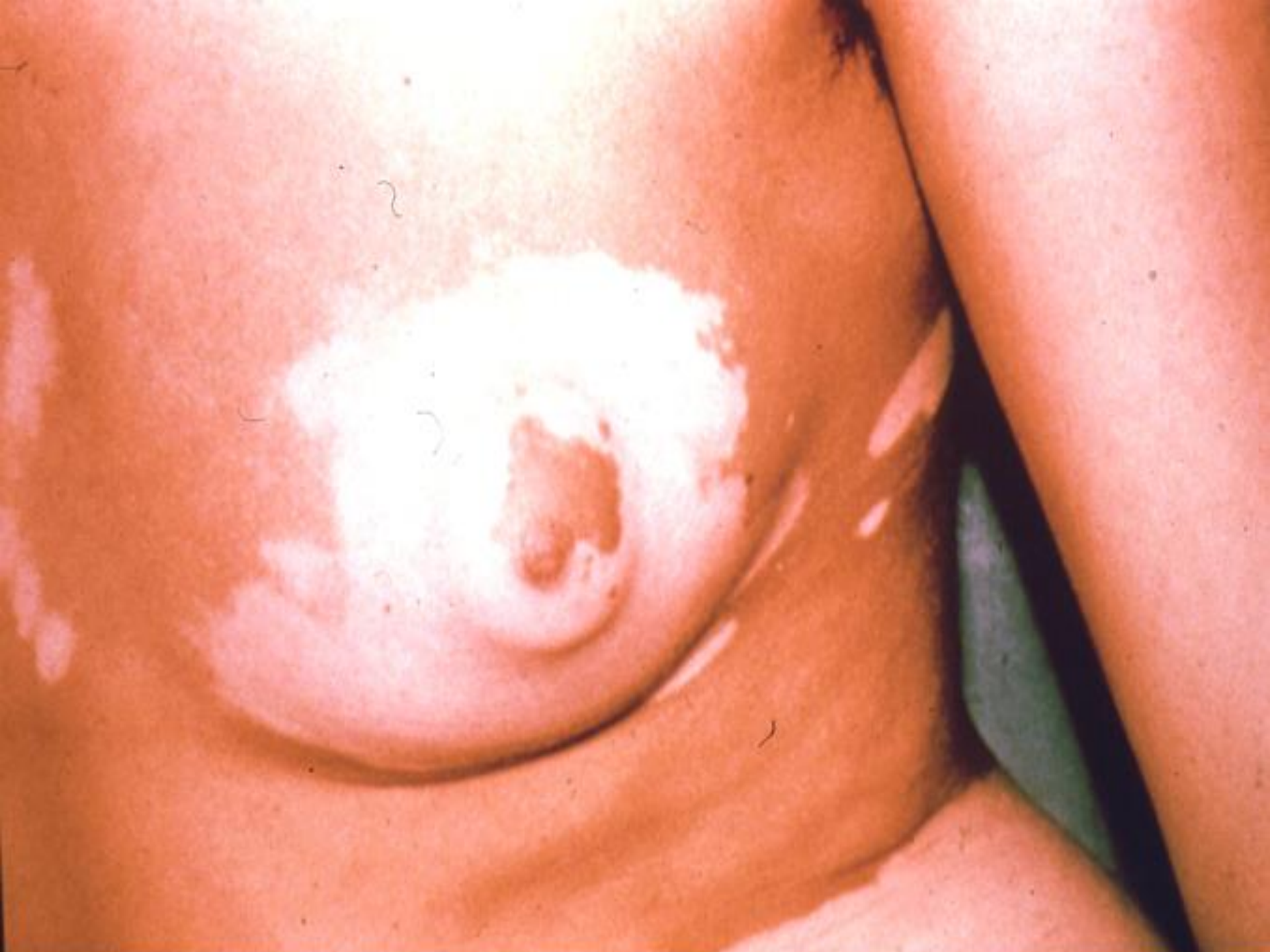- TYPE OF LESION
- SHAPE OF INDIVIDUAL LESION
- ARRANGEMENT OF MULTIPLE LESIONS
  - DISTRIBUTION



# PHYSICAL EXAMINATION

## MACULE

- CIRCUMSCRIBED, FLAT LESION WITH ABNORMAL COLOR
  - WHITE / BLACK / GRAY / BLUE / BROWN / RED
    - NO TEXTURAL CHANGES
    - NO ELEVATION OR DEPRESSION
      - TOOL: SIDE LIGHTING



# PHYSICAL EXAMINATION

## PAPULE

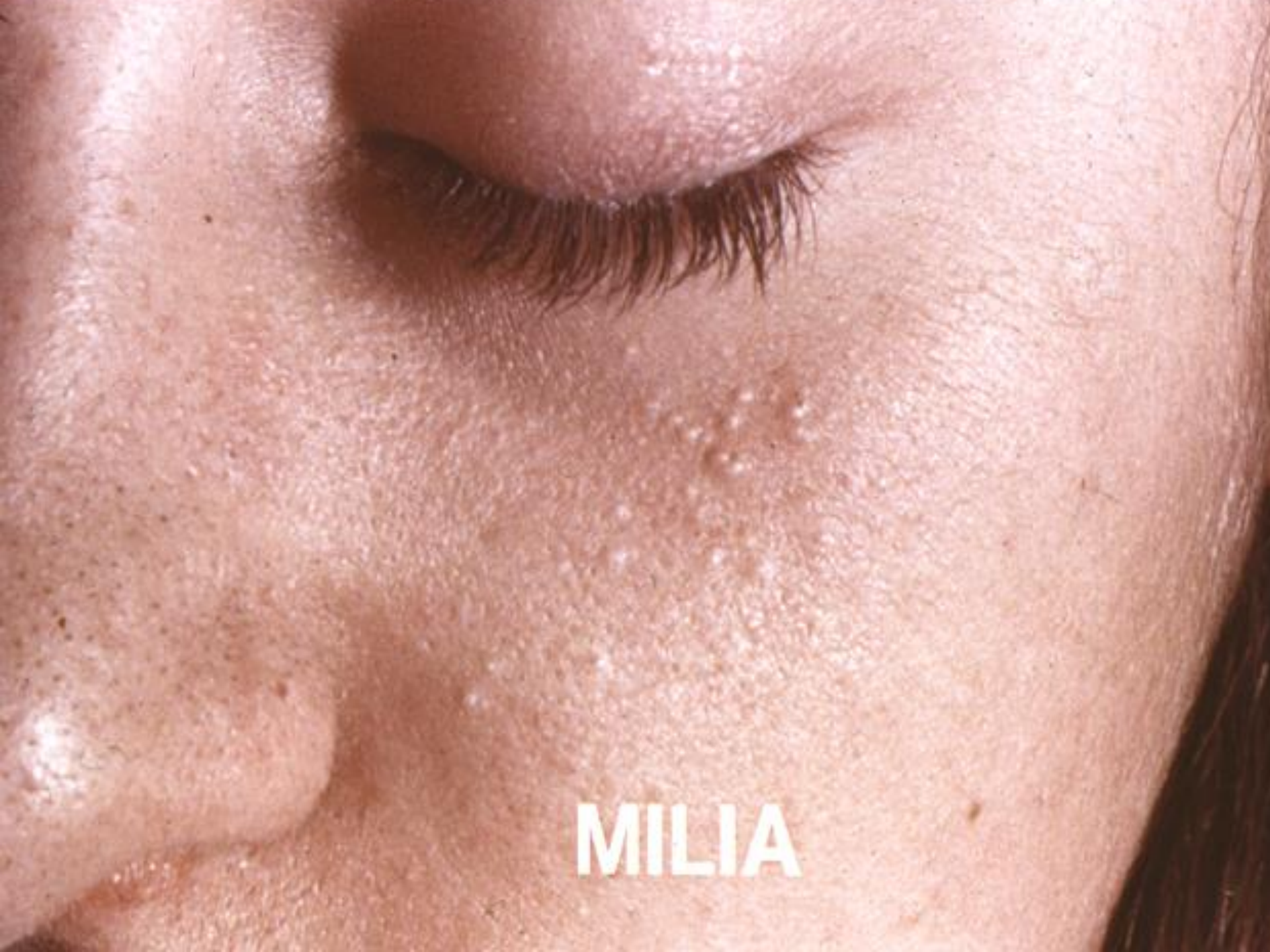**SOLID, ELEVATED LESION LESS THAN ONE CENTIMETER IN SIZE**

- **VARIABLE SHAPES**

**DOME-SHAPED, FLAT TOPPED, UMBILICATED, ACUMINATE, FOLLICULAR**

- **USUALLY DENOTES INFILTRATION OR HYPERPLASIA**

- **TOOL: SIDE LIGHTING, PALPATION**



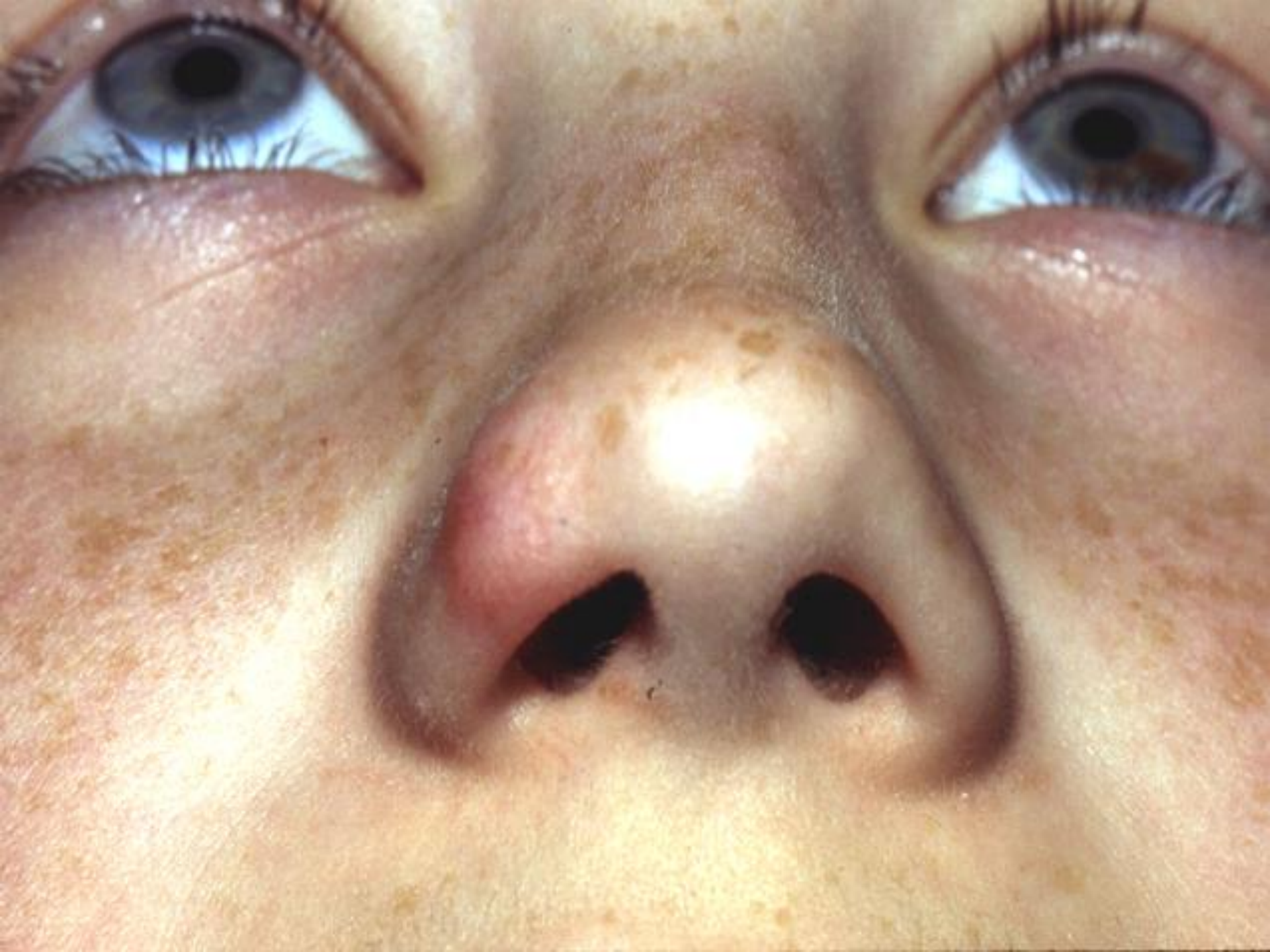**MILIA**

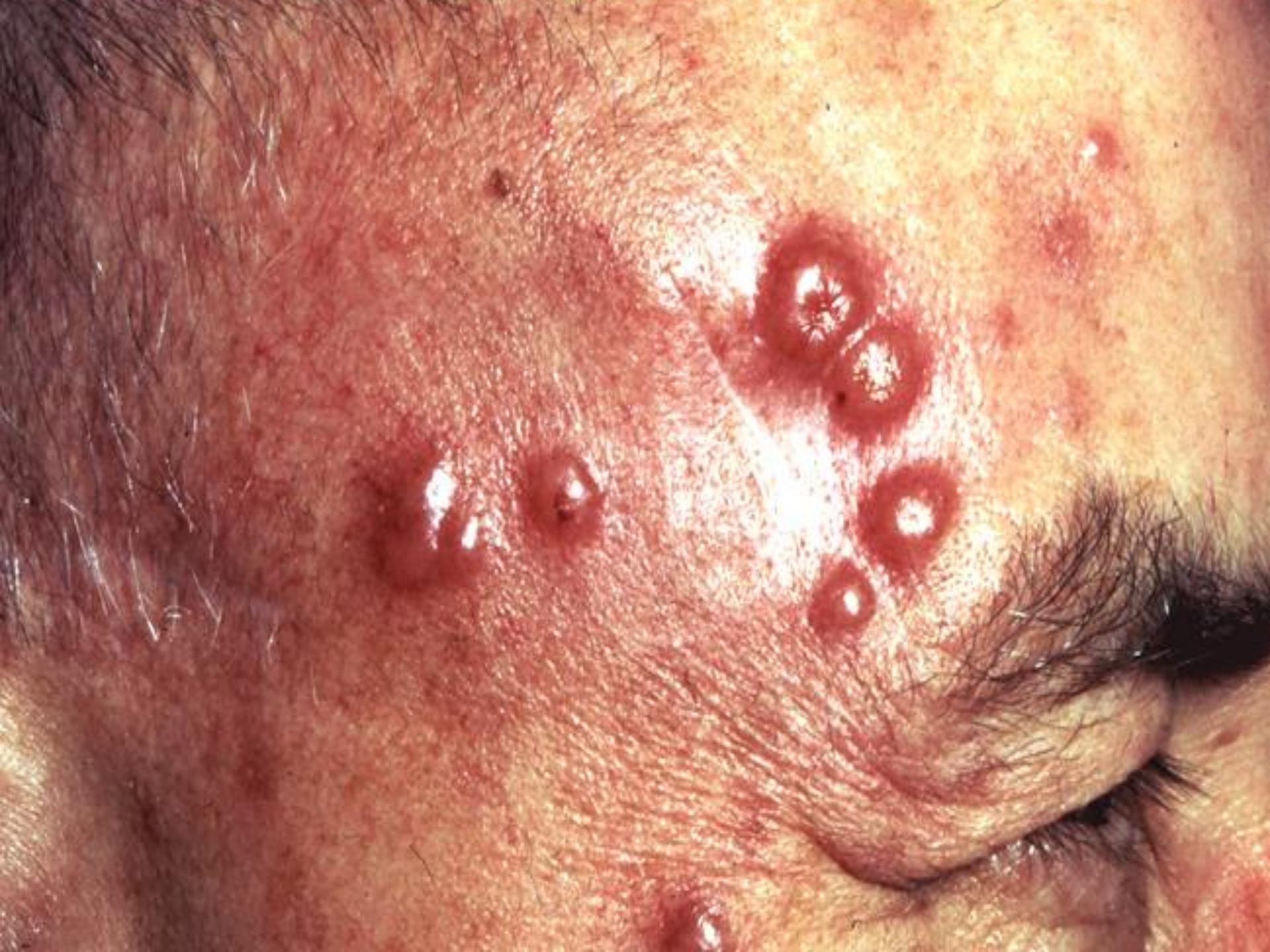# PHYSICAL EXAMINATION

## NODULE

**SOLID, PALPABLE, ROUND TO ELLIPSOIDAL LESION LARGER THAN A PAPULE**

- CAN INVOLVE ALL LAYERS OF SKIN
- CAN REPRESENT COALESCING OF PAPULES
- USUALLY DENOTES INFILTRATION OR HYPERPLASIA
  - TOOL: VISUAL, PALPATION



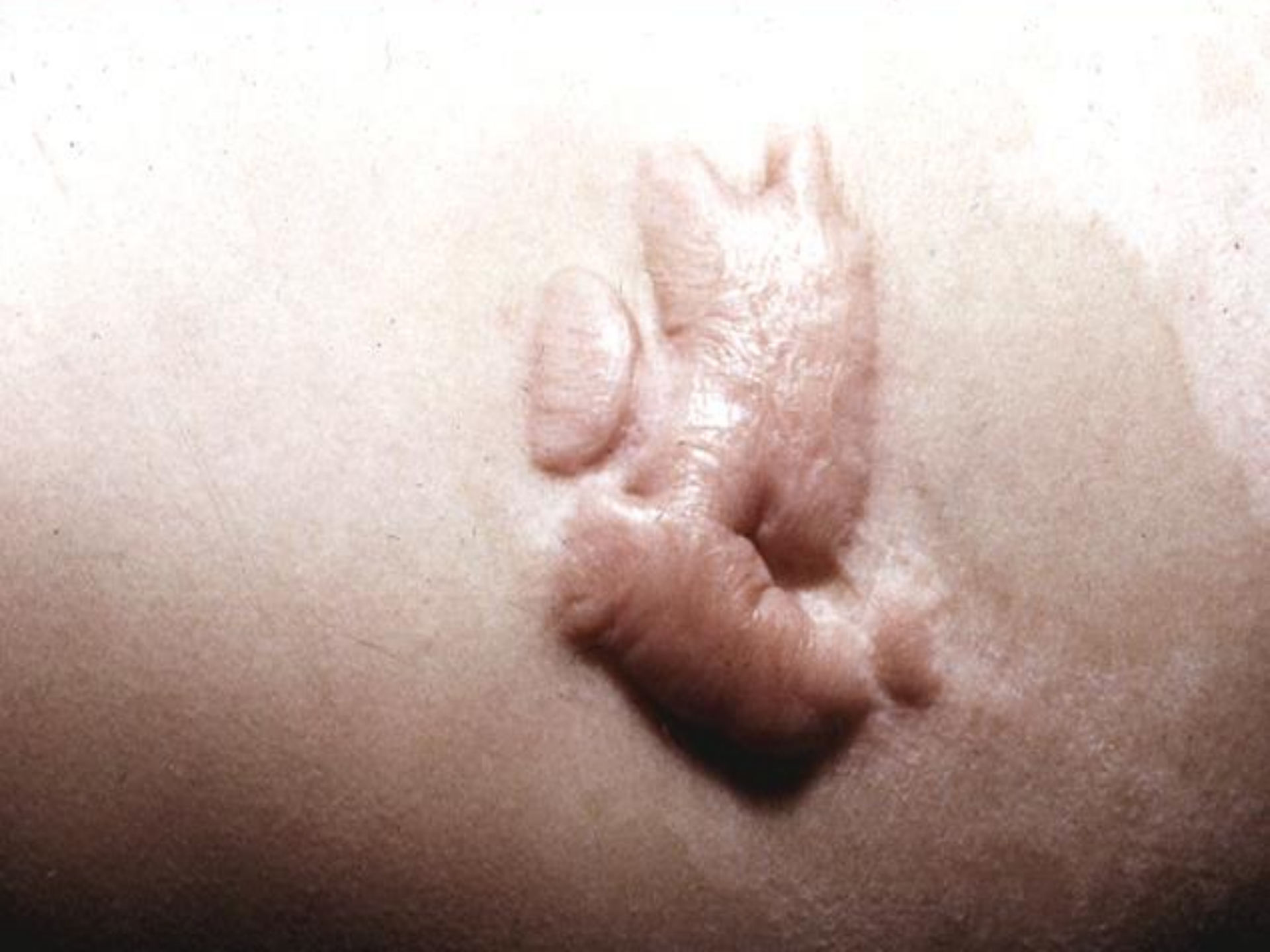

# PHYSICAL EXAMINATION

## TUMOR

### SOLID OR SOFT LARGER MASS

- CAN BE BENIGN OR MALIGNANT
  - TOOL: VISUAL, PALPATION

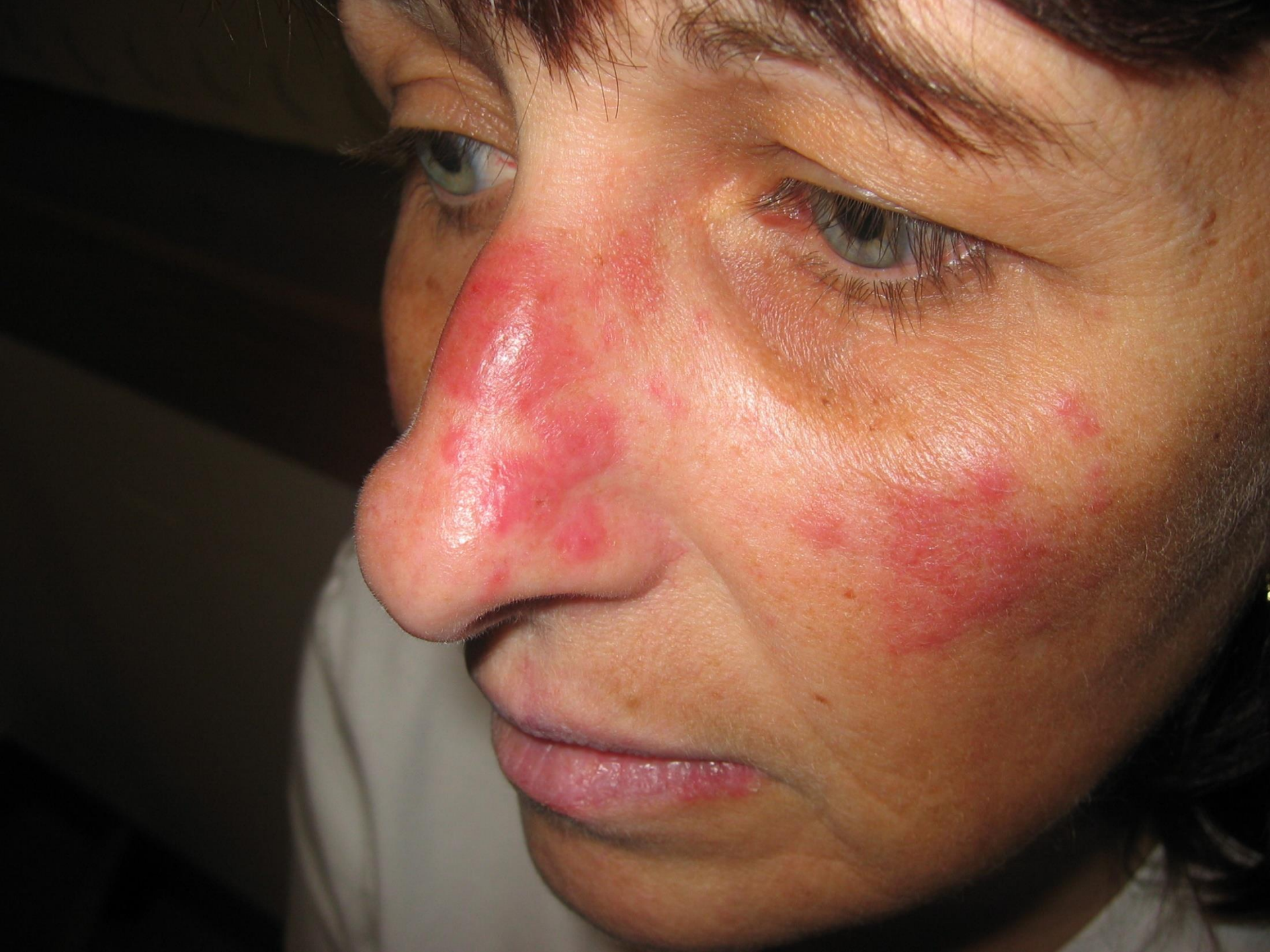

# PHYSICAL EXAMINATION

## PLAQUE

### LARGE, FLAT-TOPPED ELEVATION

- CAN INVOLVE ALL LAYERS OF SKIN
  - VARIABLE SKIN SURFACE AND PALPABILITY
- CAN REPRESENT COALESCING PAPULES
  - “PATCH” = PLAQUE WITH SCALE
  - TOOL: SIDE LIGHTING, PALPATION

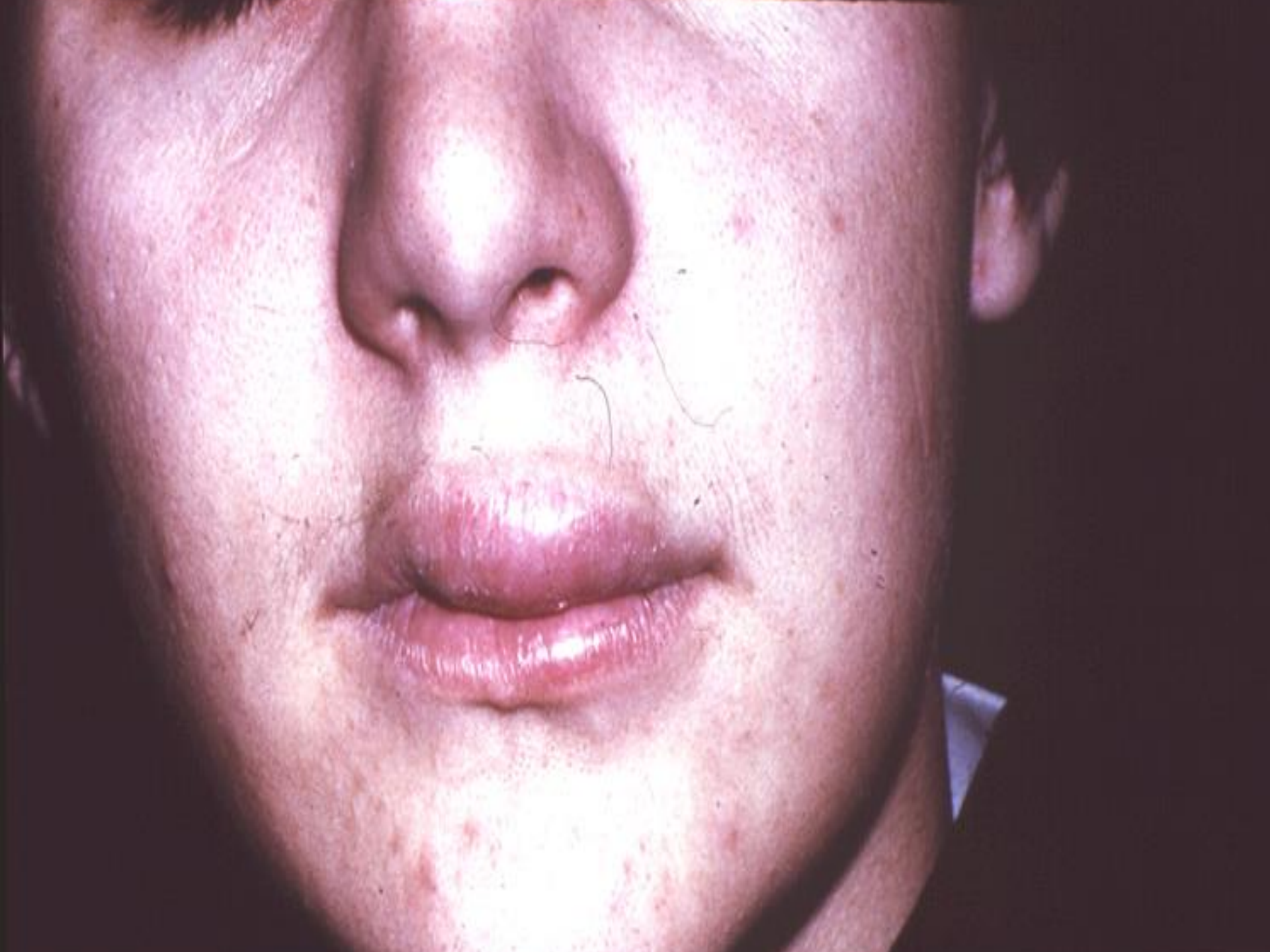

# PHYSICAL EXAMINATION

## WHEAL

**ROUND OR FLAT-TOPPED  
COMPRESSIBLE, TRANSIENT  
ELEVATION**

- **ONLY DERMIS INVOLVED**
- **IMPLIES EDEMA, NO INFILTRATE**
  - **URTICARIA, HIVES**
  - **TOOL: PALPATION**

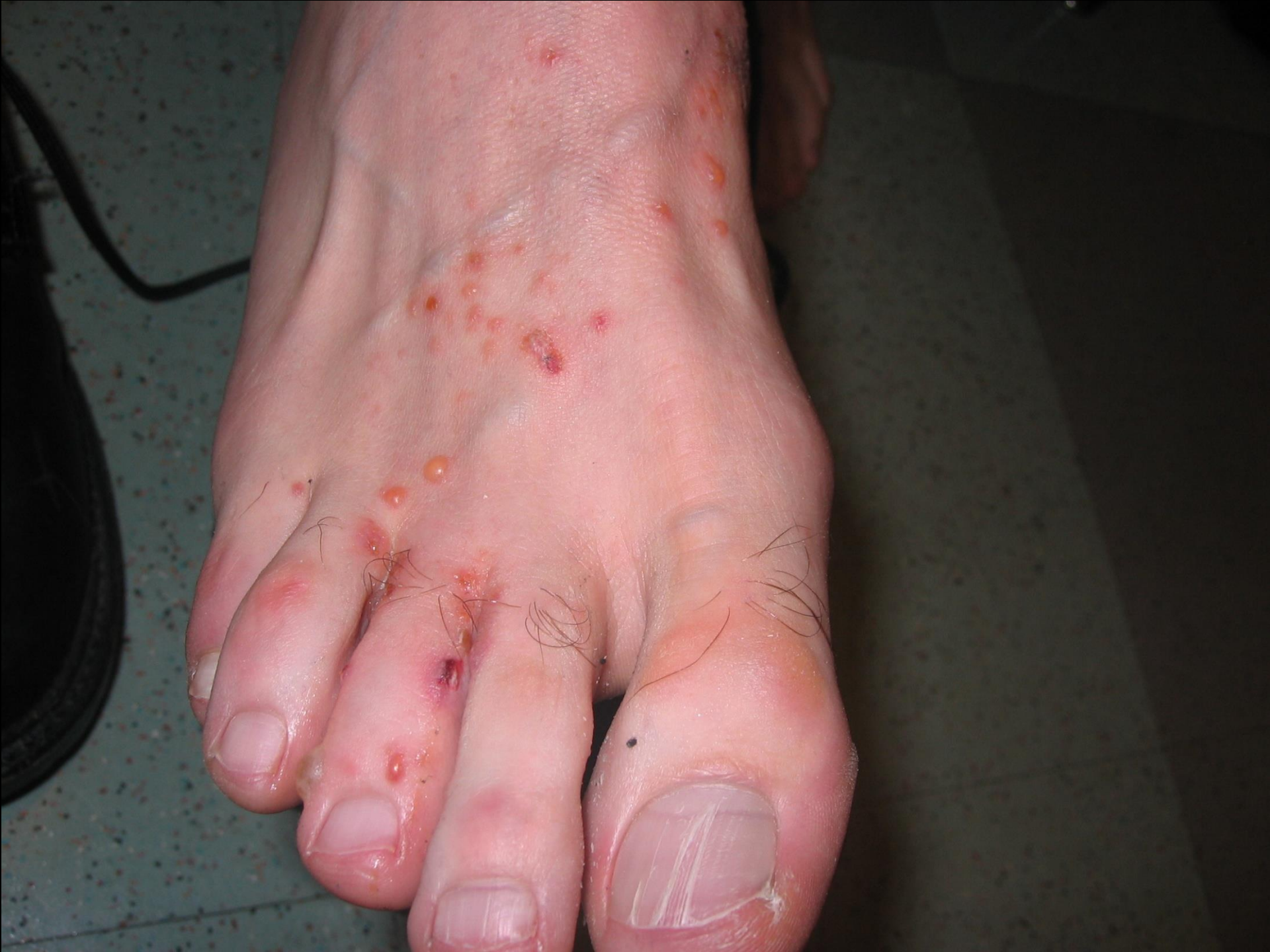

# PHYSICAL EXAMINATION

## VESICLE

**CIRCUMSCRIBED ELEVATION OF  
SMALL DIAMETER WITH NON-  
PURULENT FLUID**

- 0.5 CENTIMETER OR LESS
- CAN INVOLVE THE EPIDERMIS (FLACCID) OR DERMIS (TENSE) FLUID CAN VARY IN COLOR AND CONSISTENCY
  - TOOL: SIDE LIGHTING, PALPATION

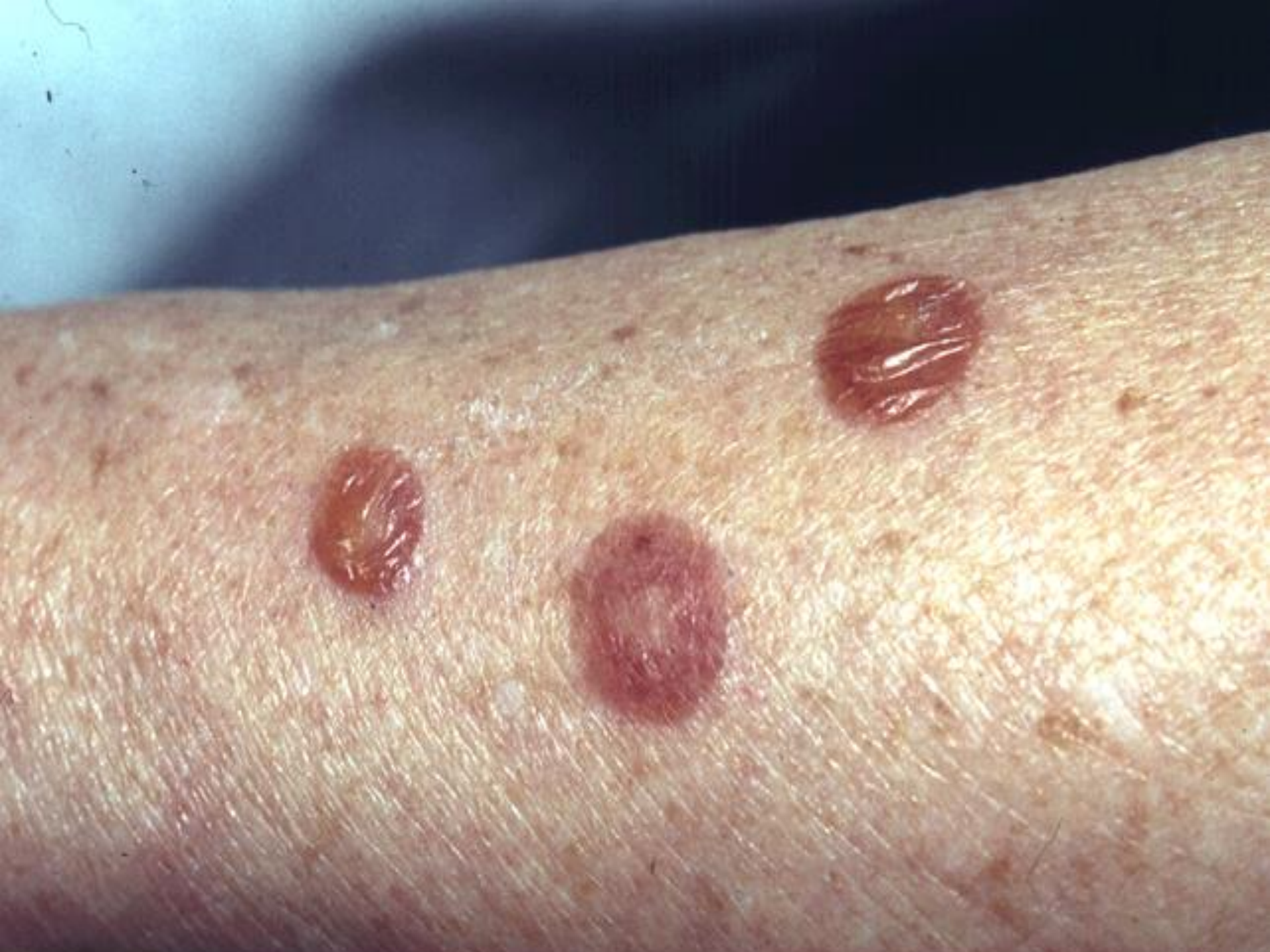

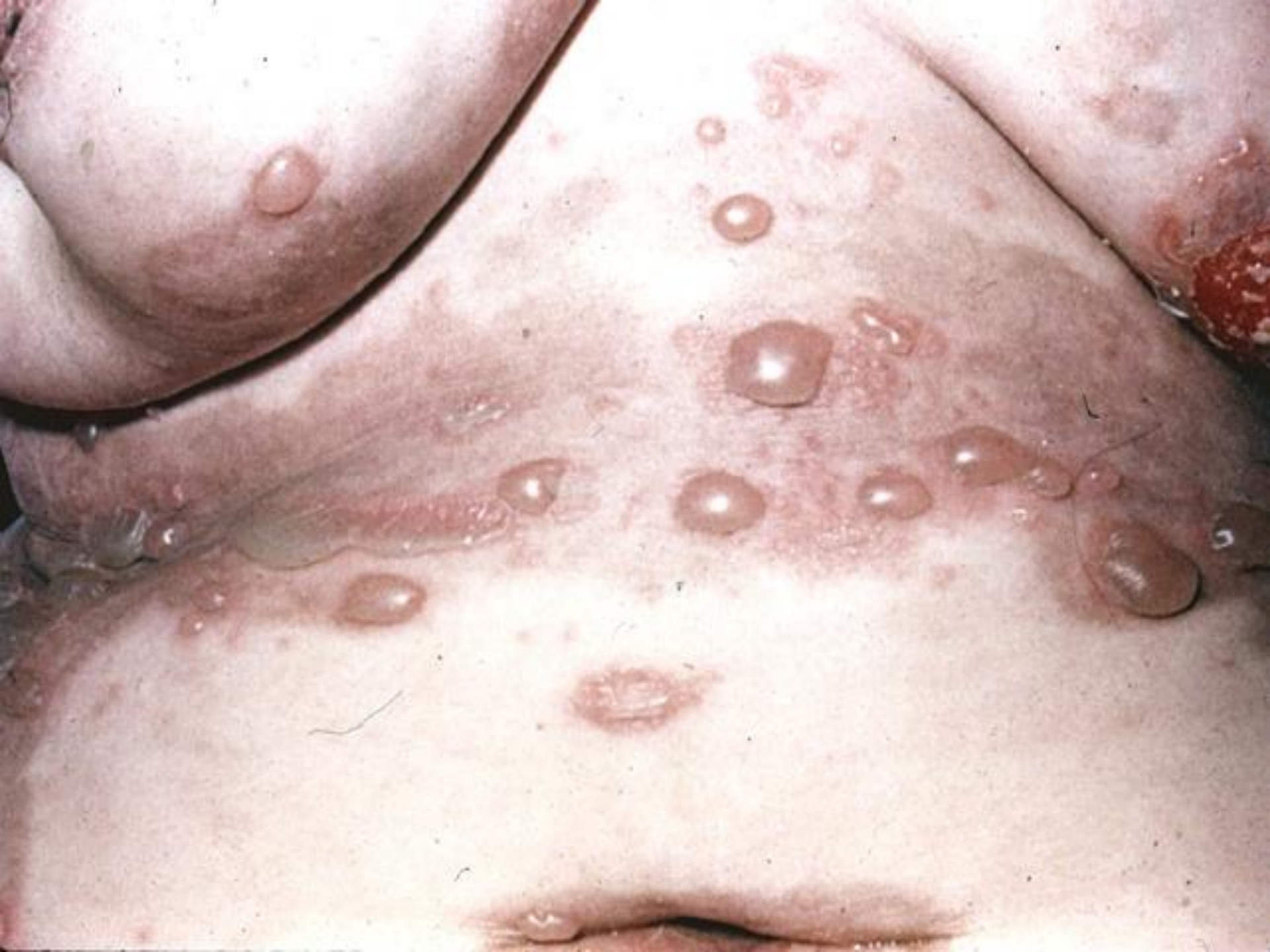# PHYSICAL EXAMINATION

## BULLA

**CIRCUMSCRIBED ELEVATION OF  
LARGER DIAMETER WITH NON-  
PURULENT FLUID**

- **CAN INVOLVE EPIDERMIS (FLACCID) OR  
DERMIS (TENSE)**
  - **FLUID CAN VARY IN COLOR AND  
CONSISTENCY**
    - **TOOL: PALPATION**



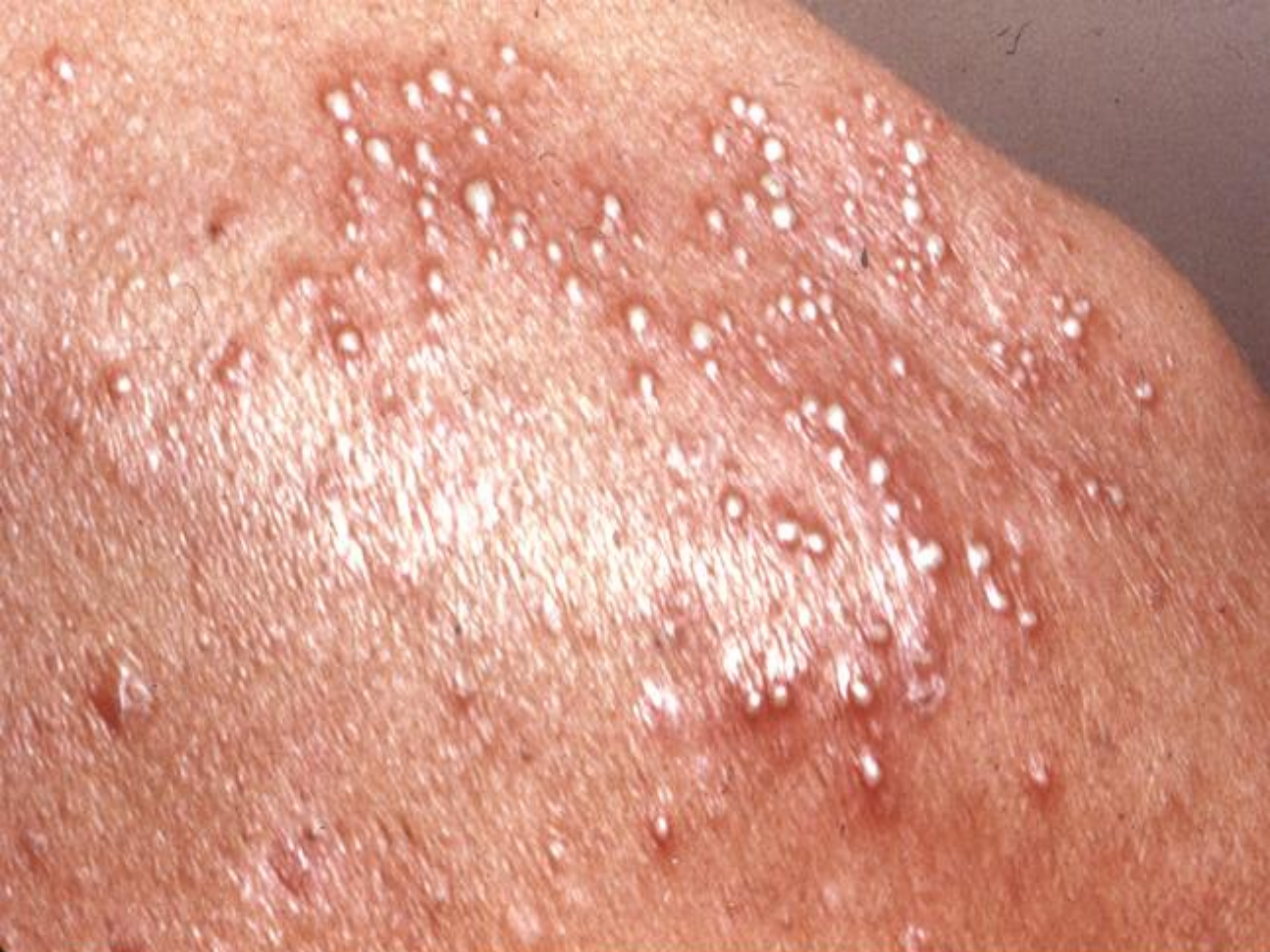

# PHYSICAL EXAMINATION

## PUSTULE

CIRCUMSCRIBED ELEVATION WITH  
PURULENT FLUID OF ANY  
DIAMETER

- VARIABLE SHAPES
- TOOL: SIDE LIGHTING



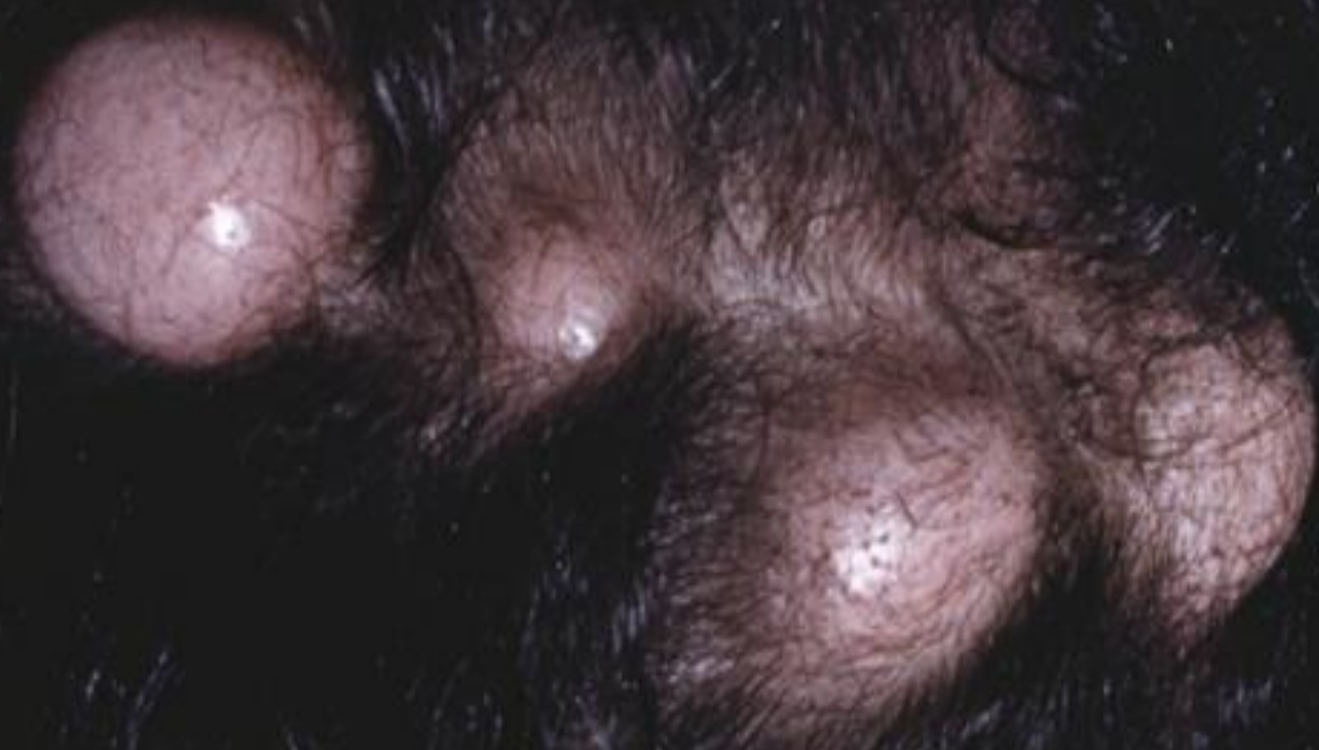# PHYSICAL EXAMINATION

## CYST

**ENCAPSULATED RESILIENT LESION  
CONTAINING LIQUID OR  
SEMISOLID MATERIAL**

- **USUALLY DOME SHAPED**
- **MAY HAVE AN EXTRUSION POINT**
  - **VARIABLE SIZE**
- **TOOL: PALPATION BETWEEN FINGERS**

**WENS**



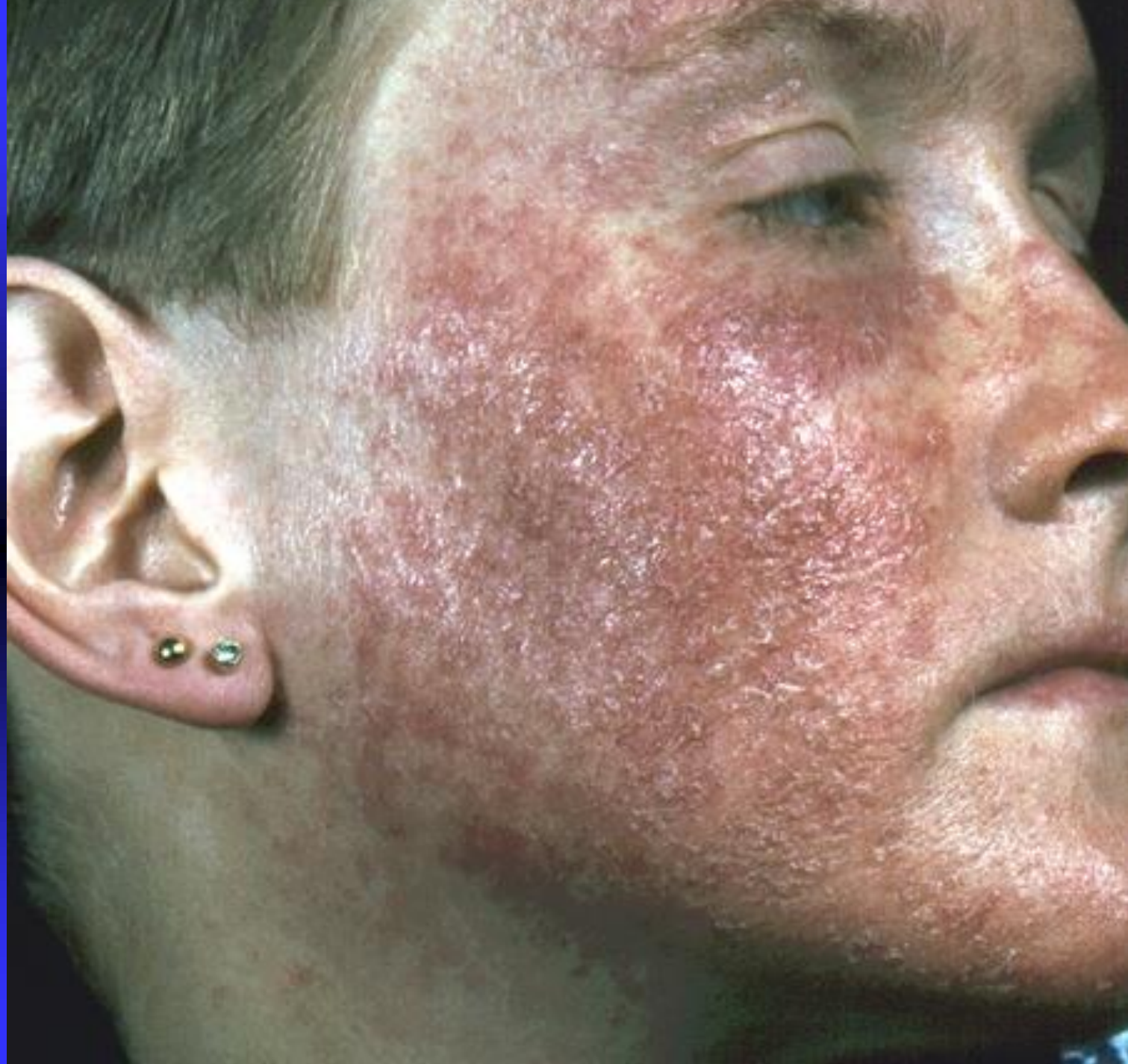# PHYSICAL EXAMINATION

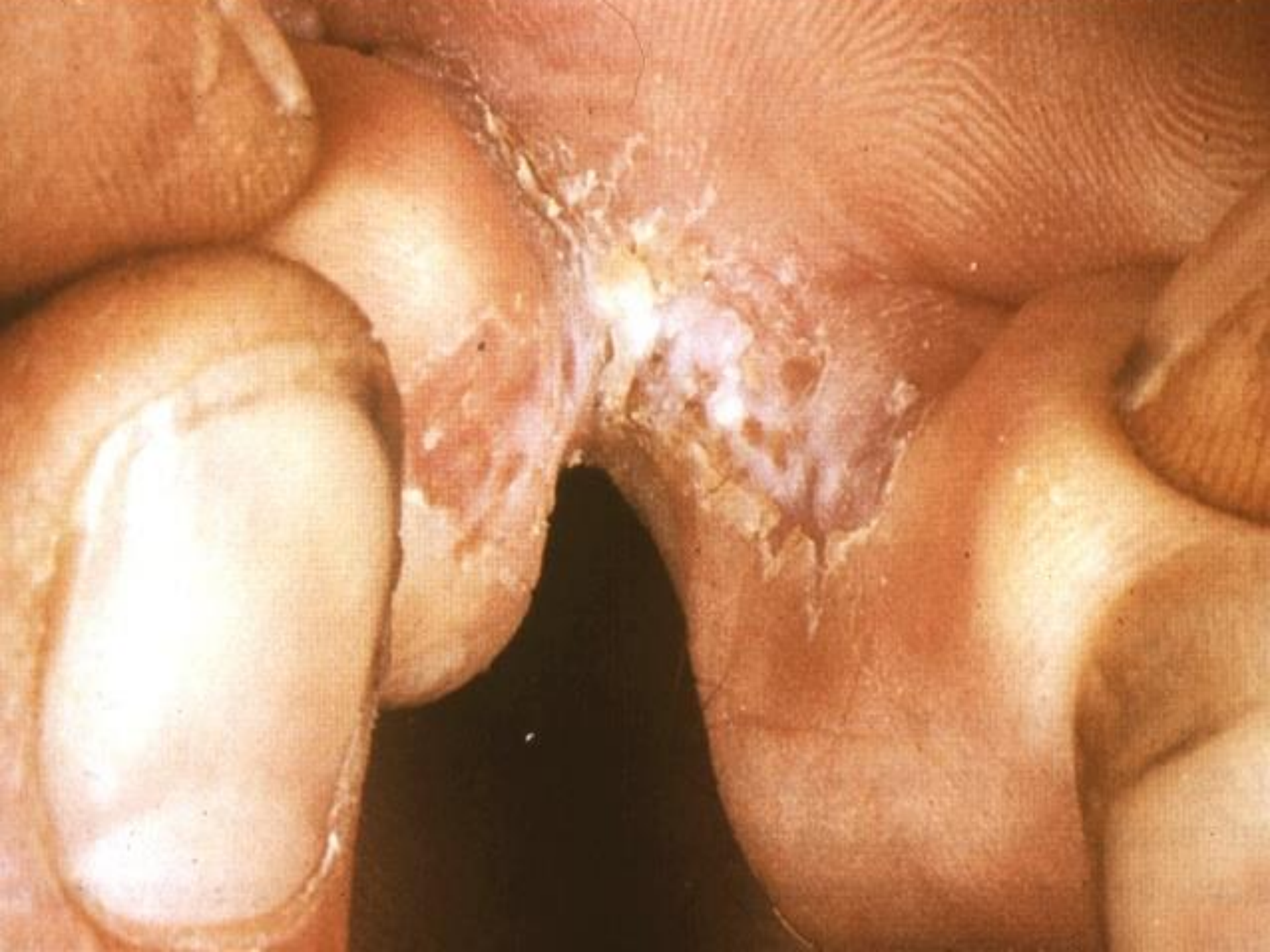## MODIFIERS/SECONDARY

- SCALE
- CRUST
- EXUDATION
- MACERATION
- LICHENIFICATION
- EXCORIATION
  - EROSION
  - FISSURE
- VEGETATION
  - COLOR

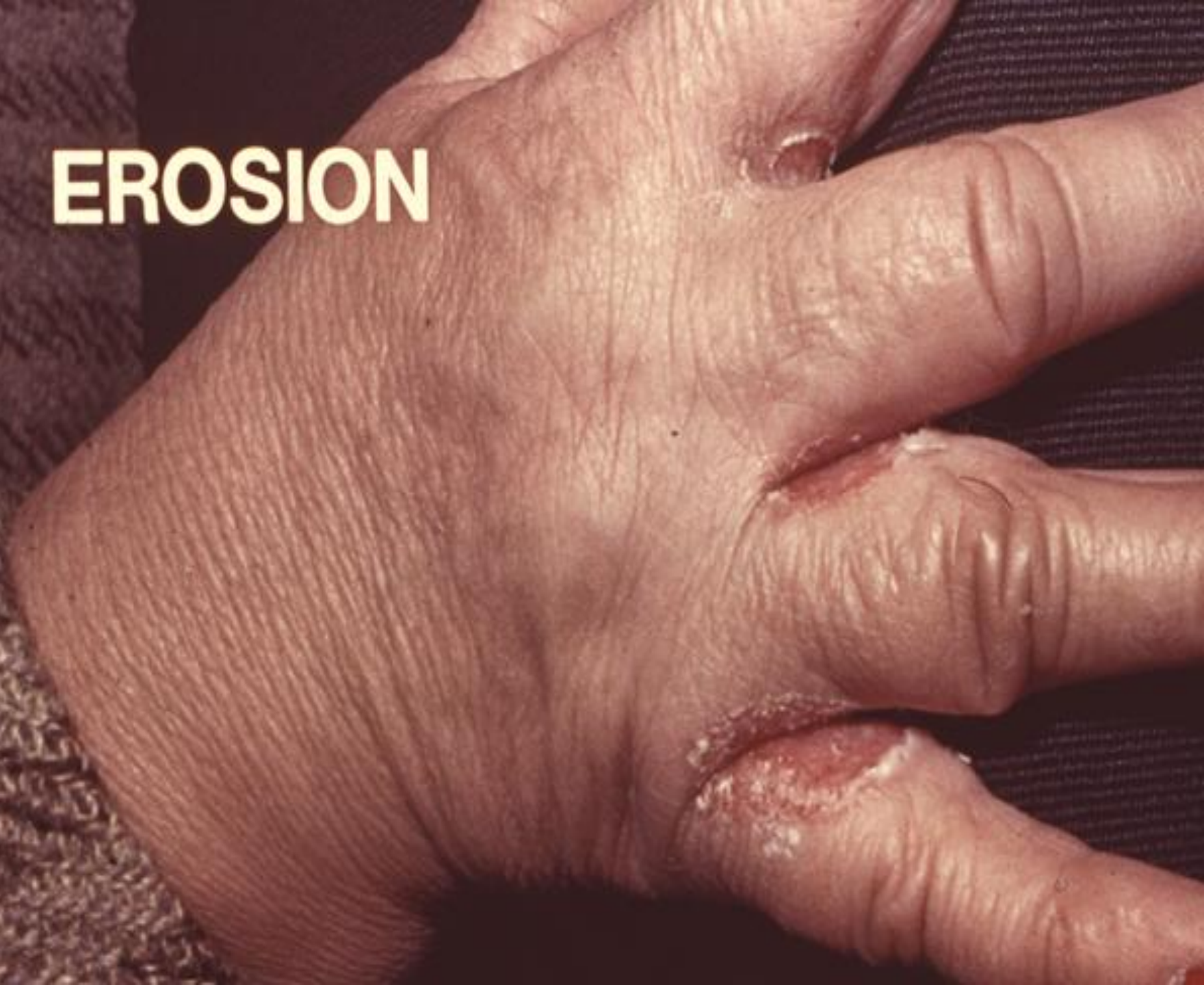A close-up photograph of human skin, likely on an arm or shoulder, showing severe dryness and scaling. The skin is covered in numerous small, white, flaky scales that are densely packed and have a rough, cracked texture. The overall color of the skin is a pale, pinkish-tan. The word "ICHTHYOSIS" is overlaid in white, bold, capital letters in the upper right quadrant of the image.

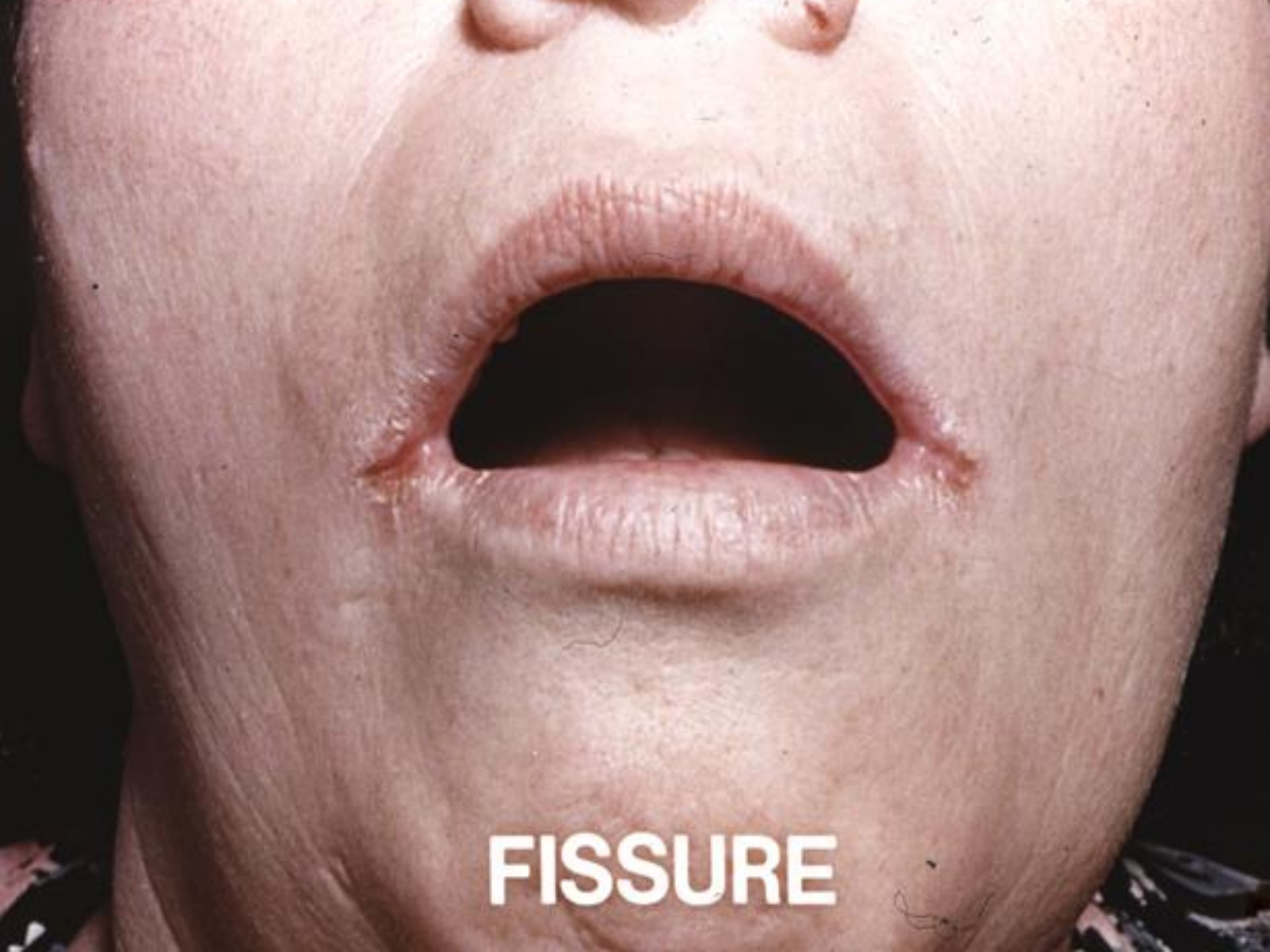**ICHTHYOSIS**





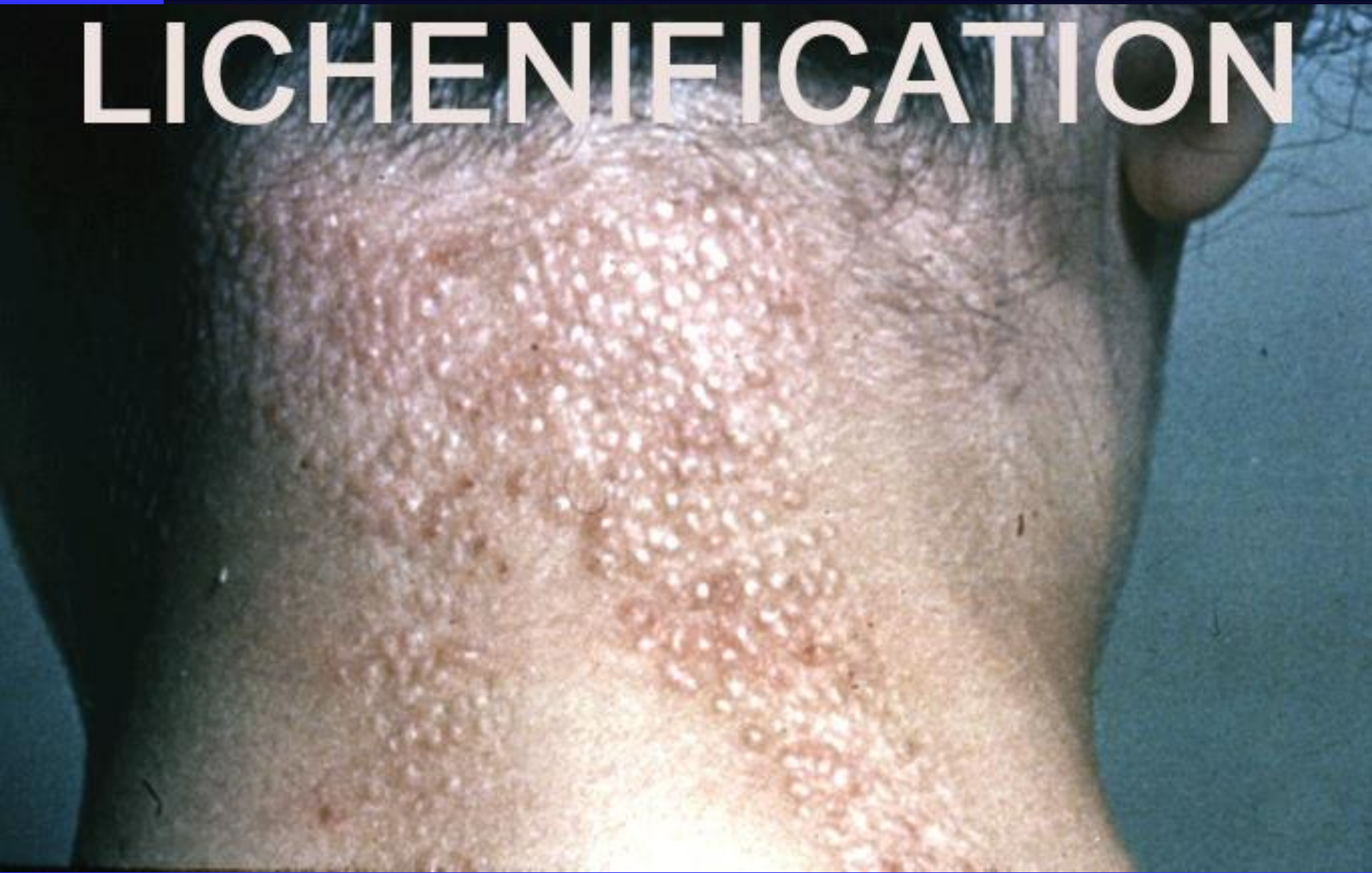
**EROSION**



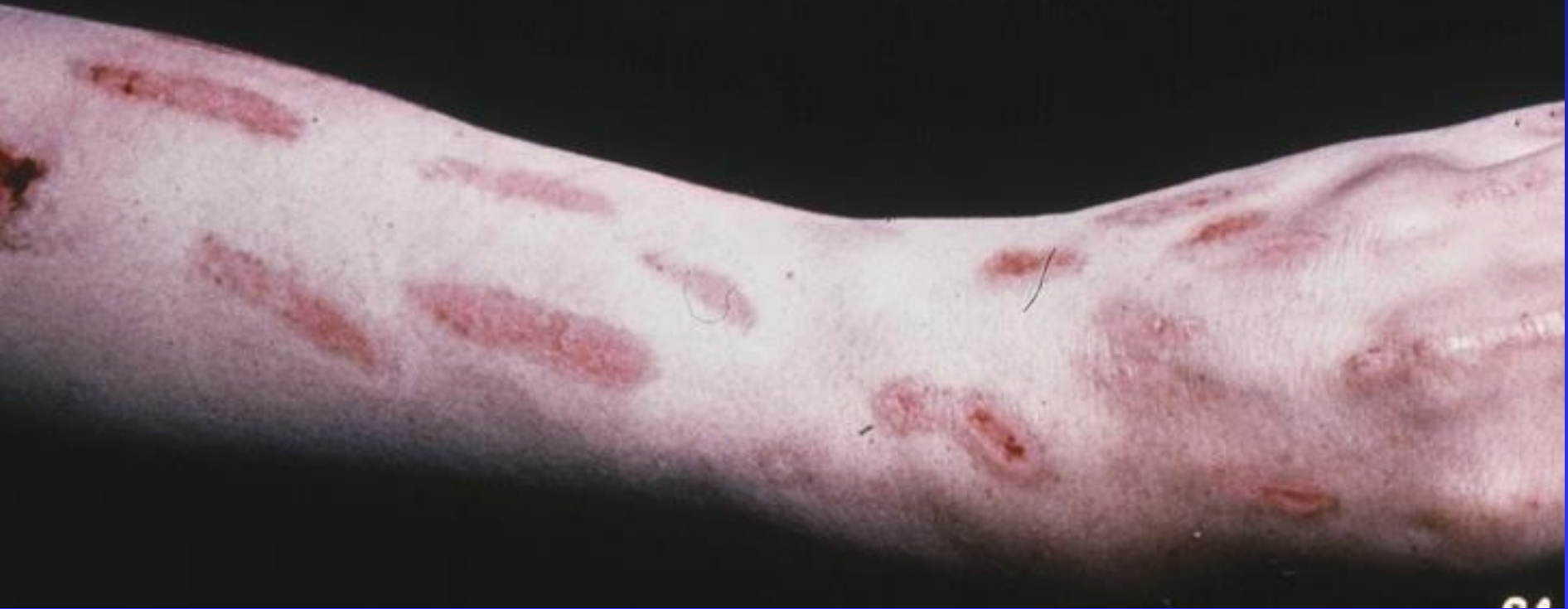

**FISSURE**

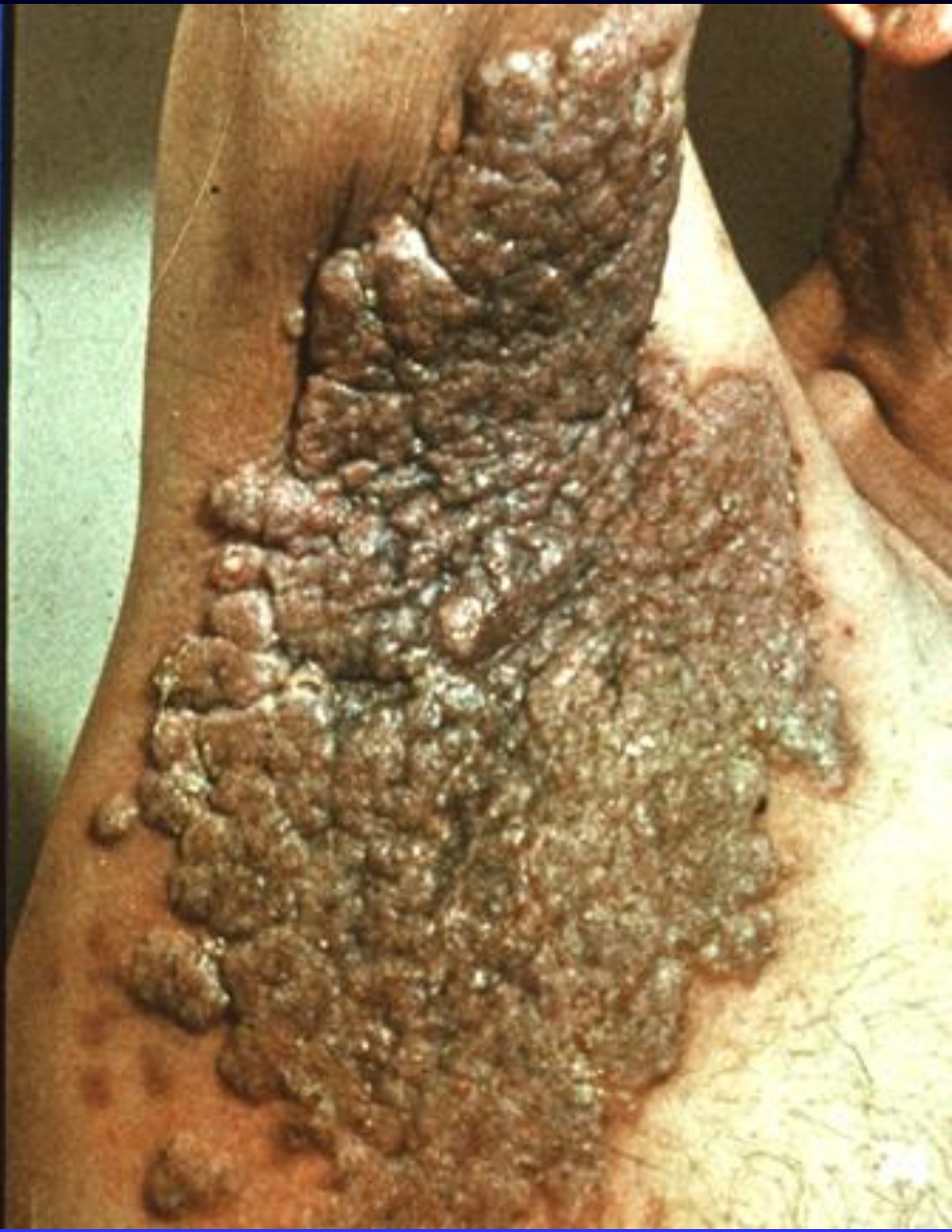# LICHENIFICATION

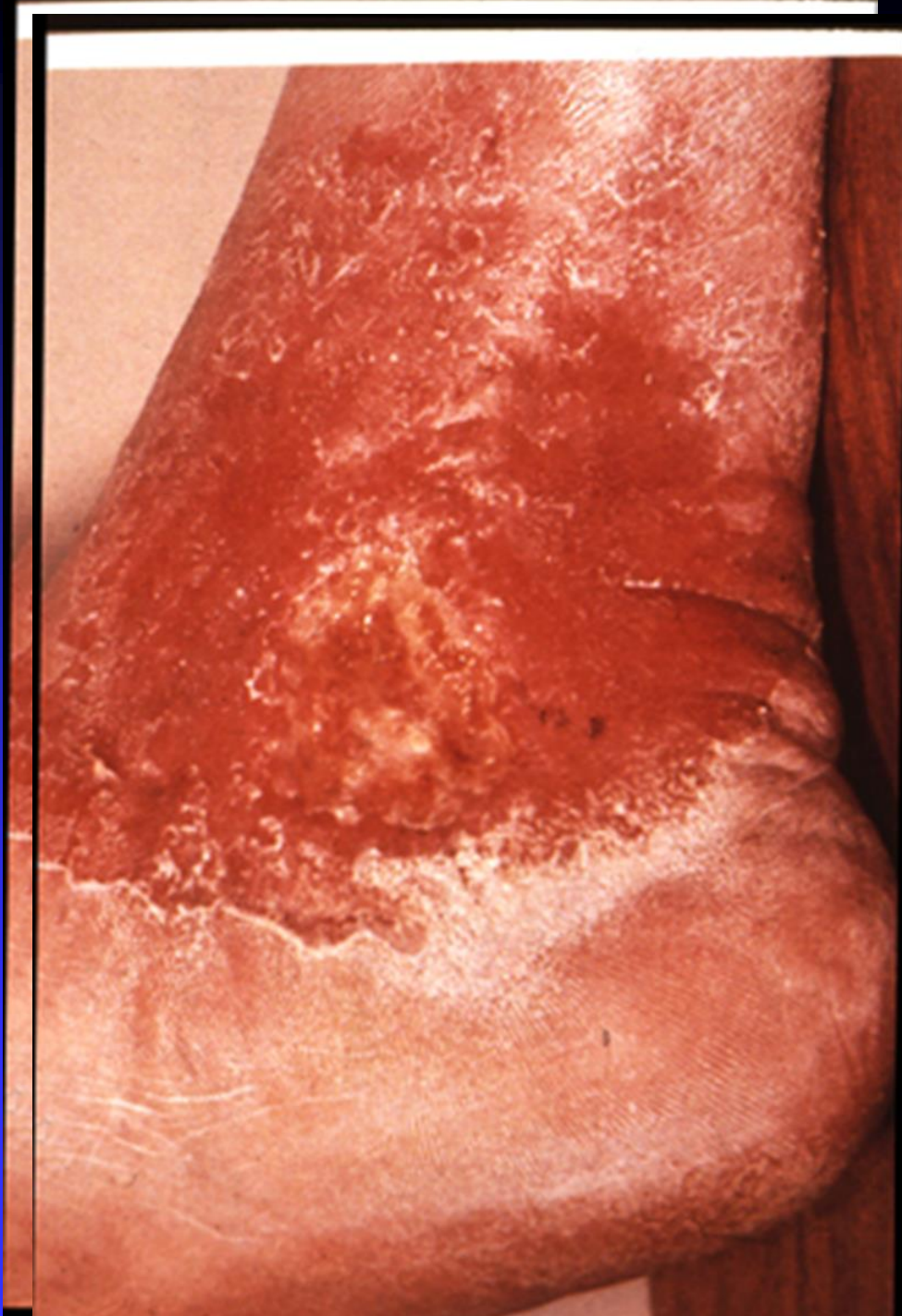

# NEUROTIC EXCORIATIONS



# VEGETATING



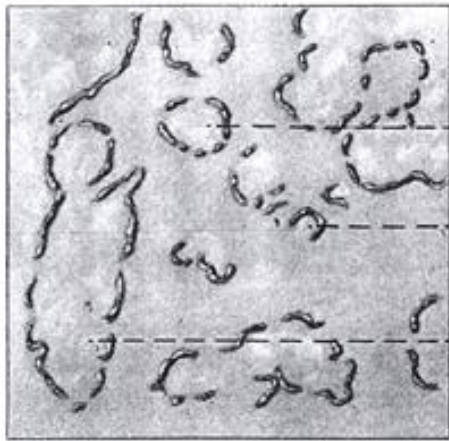




# PHYSICAL EXAMINATION

## CONFIGURATIONS

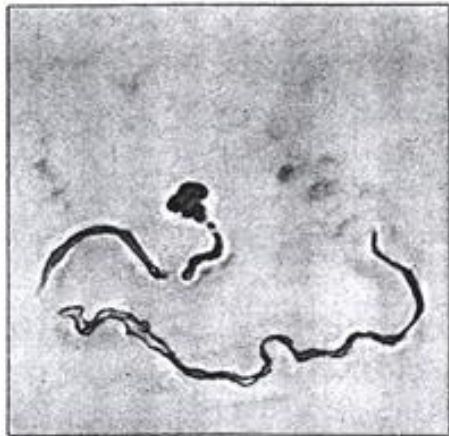- ANNULAR
- ARCIFORM
- POLYCYCLIC
- IRIS (TARGETOID)
  - LINEAR
  - SERPIGINOUS
- HERPETIFORM
- ZOSTERIFORM
- RETIFORM
  - GROUPED
- CORYMBIFORM



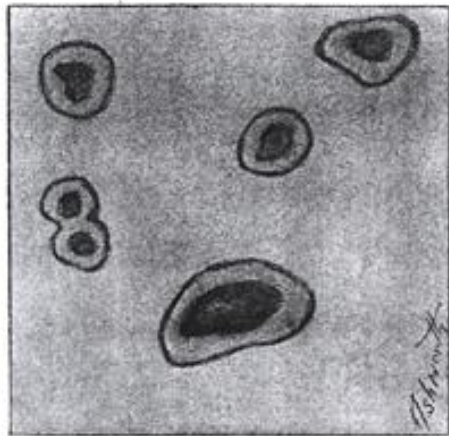
ANNULAR  
LESION

ARCIFORM  
LESION

POLYCYCLIC  
LESION

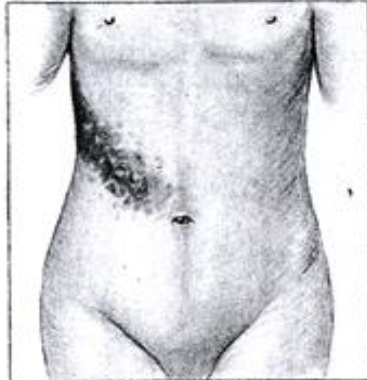

SERPIGINOUS  
LESION

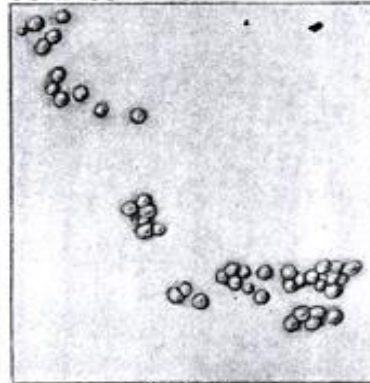

IRIS  
LESIONS

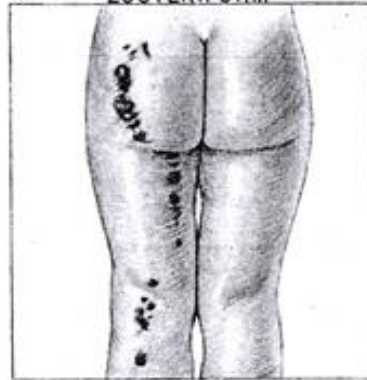
DIAGNOSIS BY CONFIGURATION



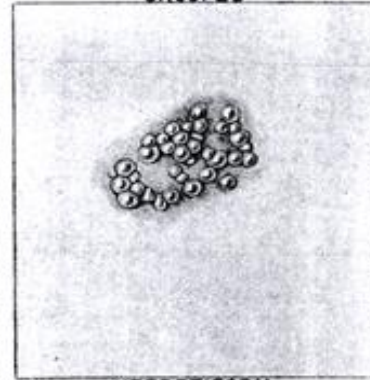
ZOSTERIFORM



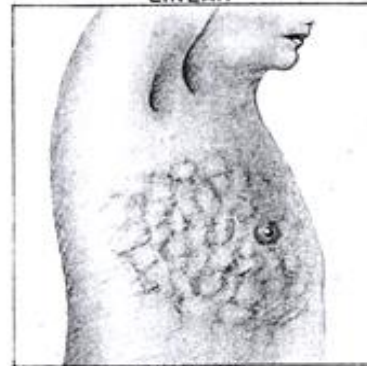
GROUPED



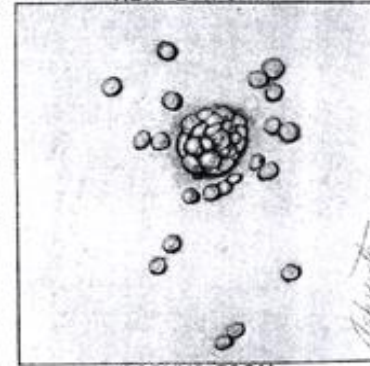
LINEAR



HERPETIFORM



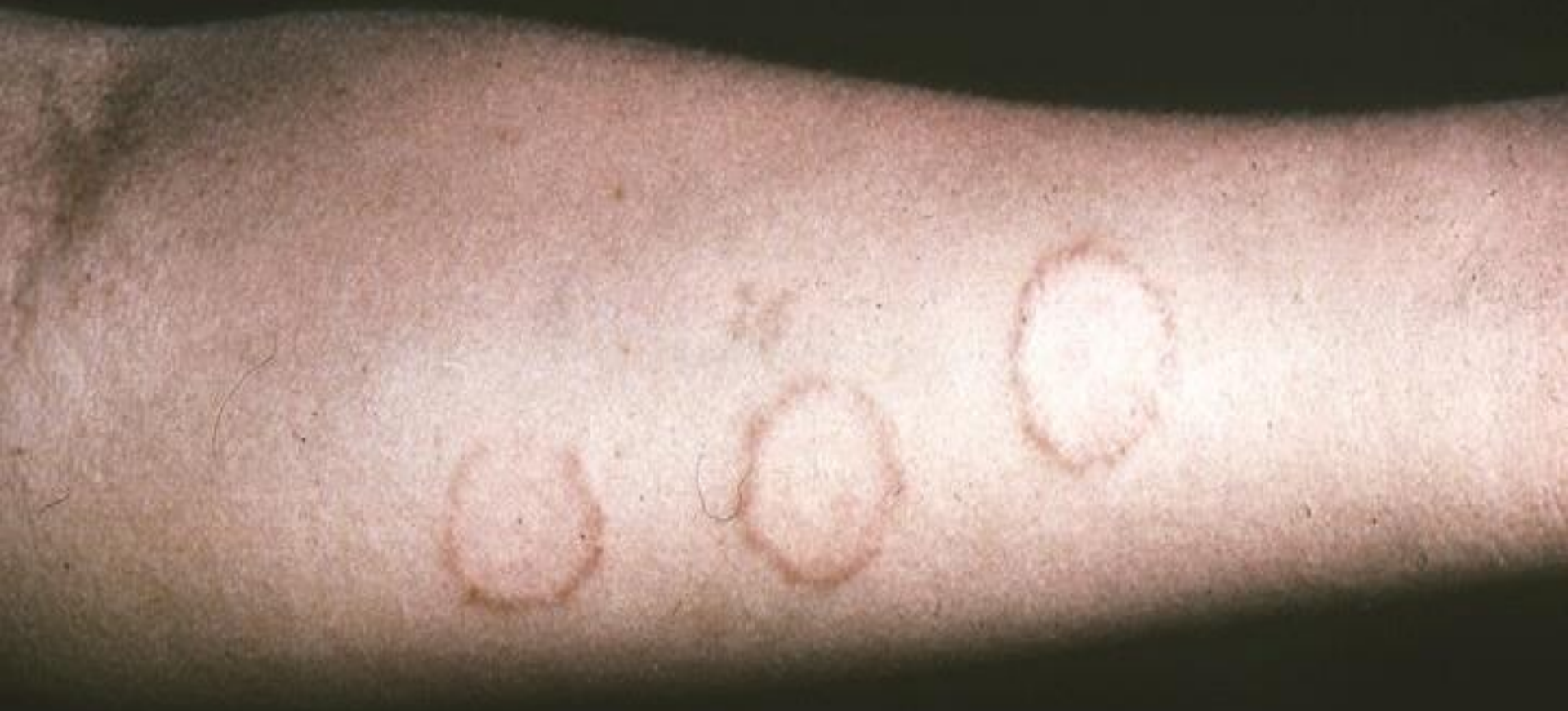RETIFORM



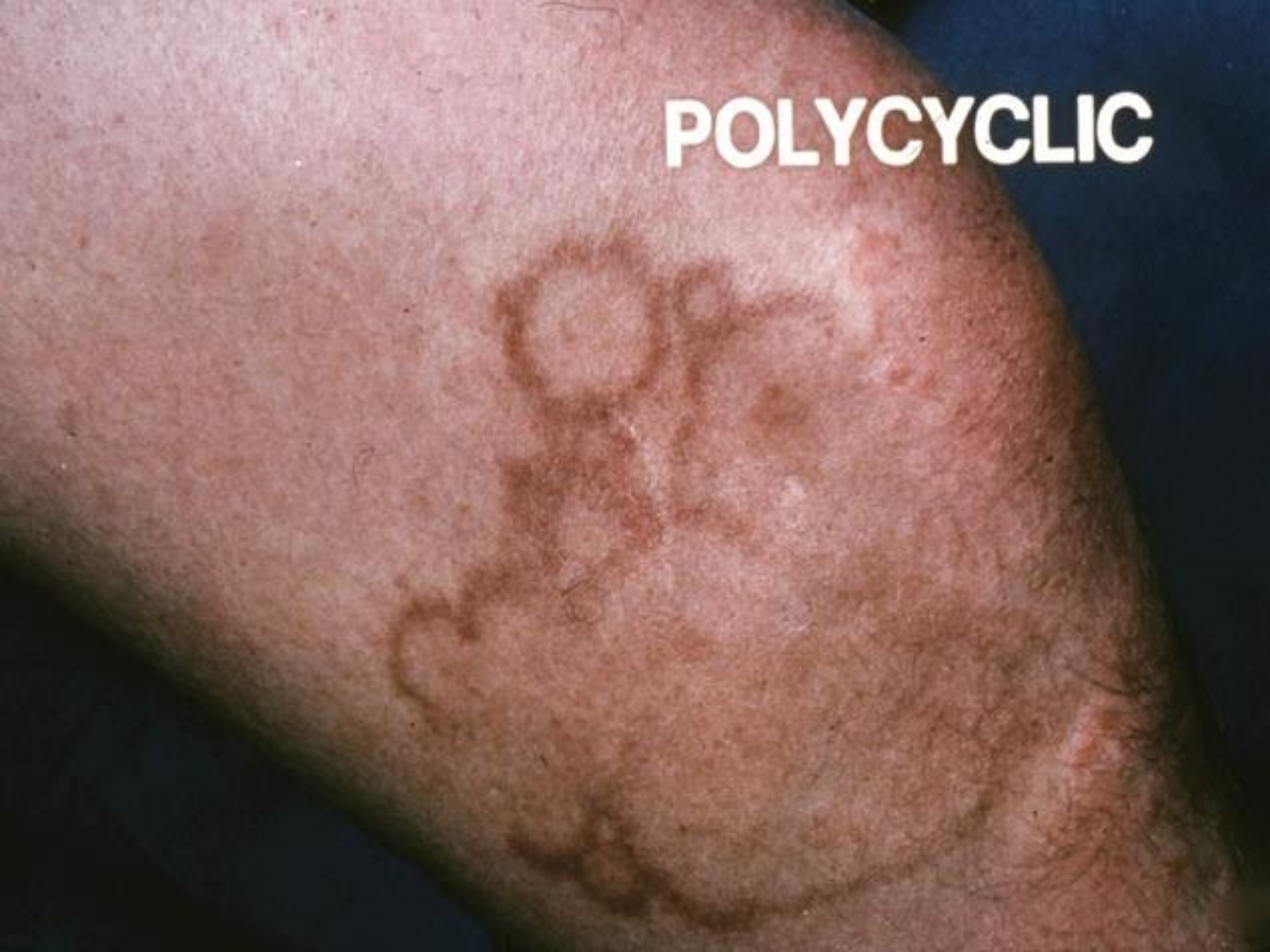CORYMBIFORM

*Johnson*

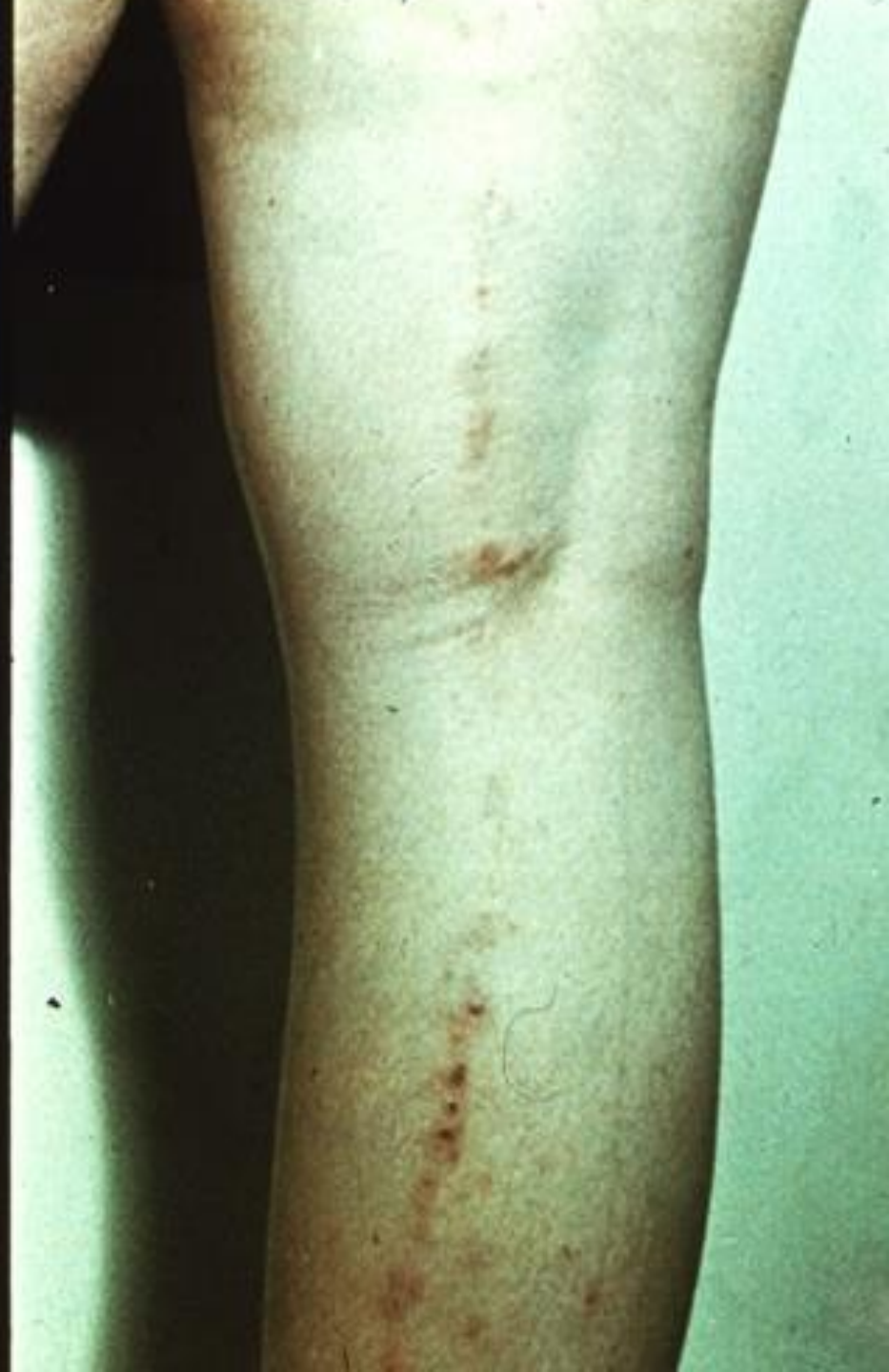**ANNULAR**



**POLYCYCLIC**



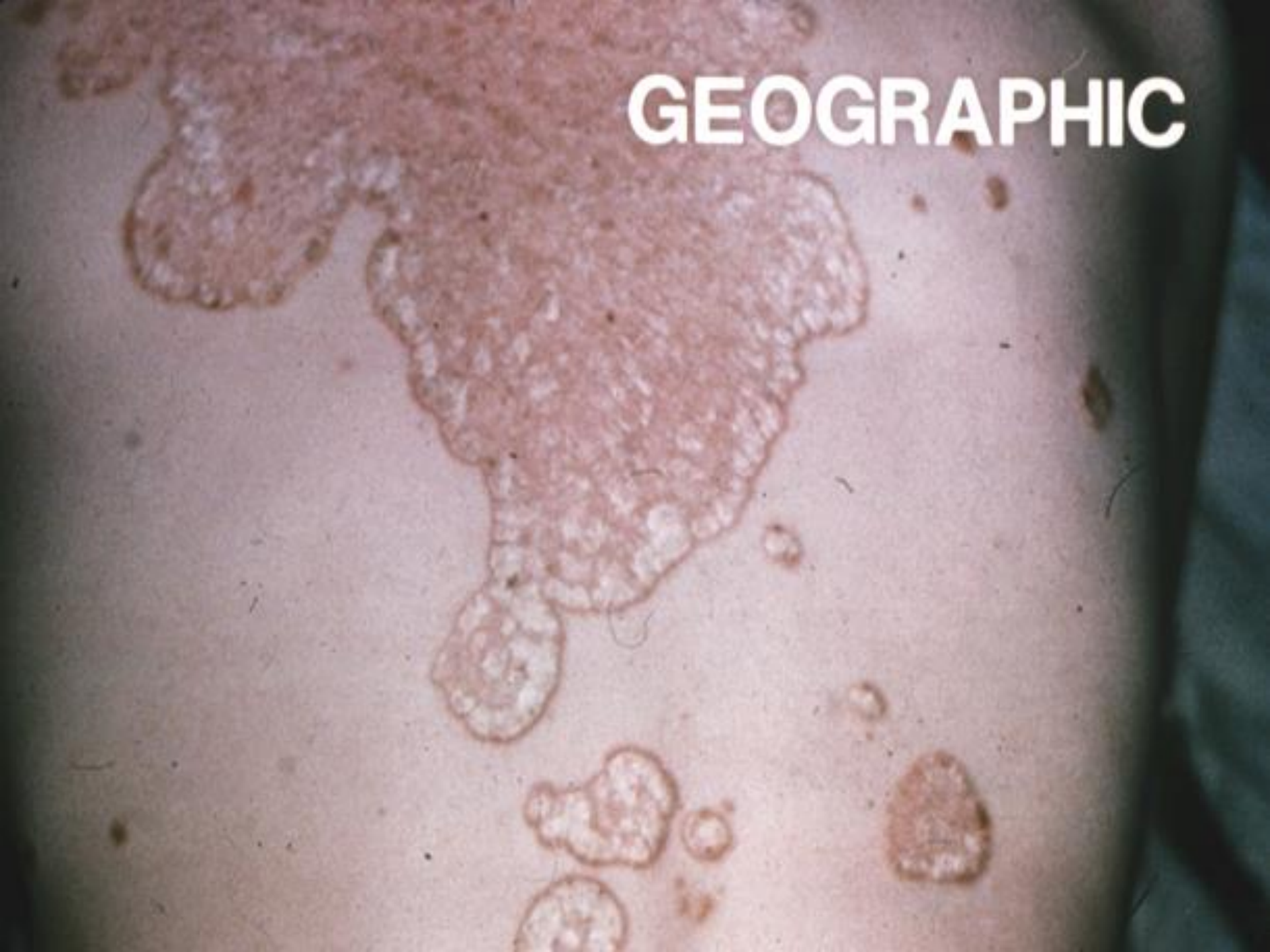
**LINEAR**





**SERPIGINOUS**

**GEOGRAPHIC**



# PHYSICAL EXAMINATION

## PATTERN RECOGNITION

- TYPE OF PRIMARY LESION(S)
  - MODIFIER(S)
- CONFIGURATION(S)
  - DISTRIBUTION

# PHYSICAL EXAMINATION

**PATTERN RECOGNITION (SAMPLE)**

## **PSORIASIS VULGARIS**

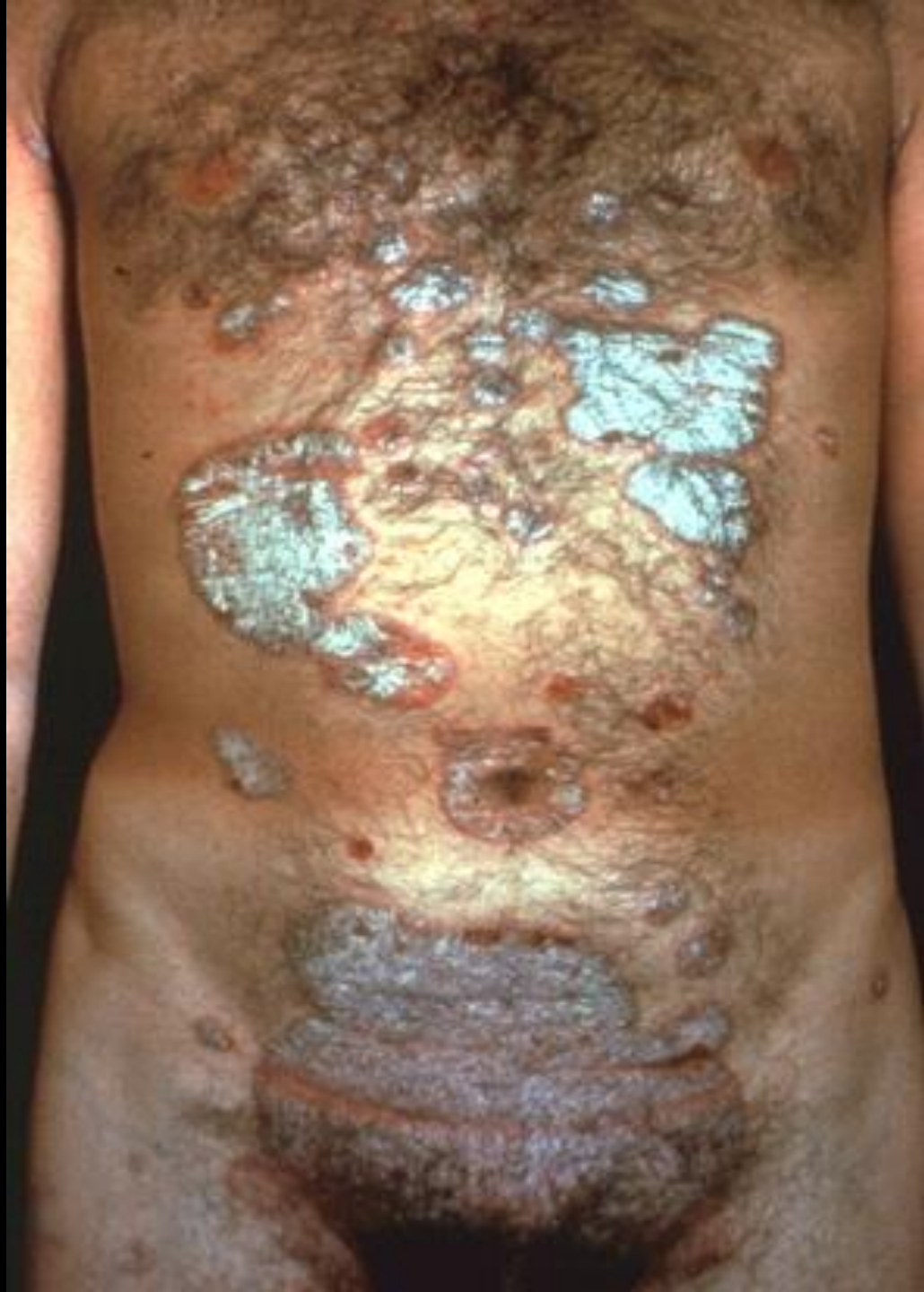**TYPE OF LESION: PLAQUE**

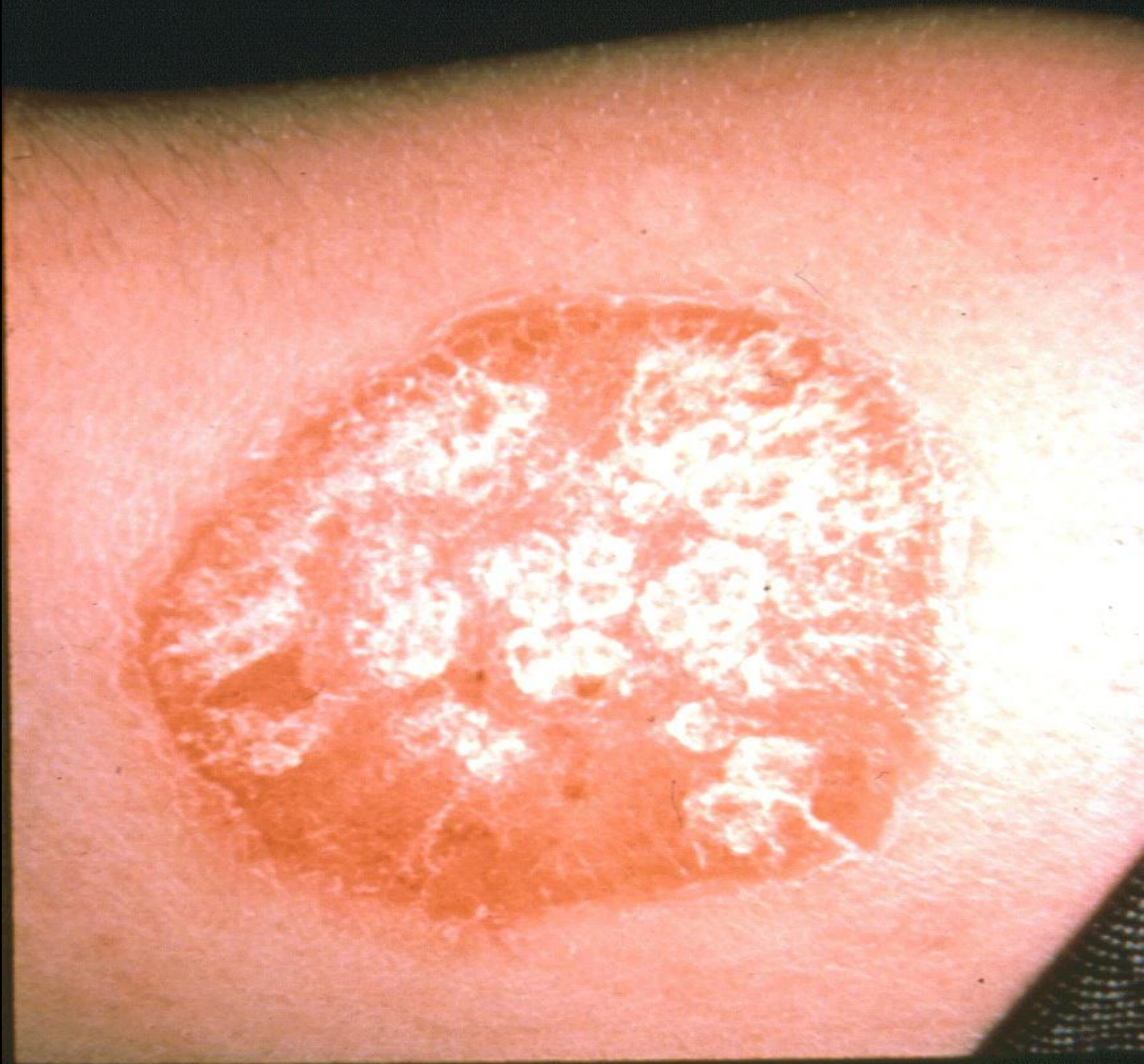**MODIFIER: SCALES**

**CONFIGURATION:**

**GROUPED/GEOGRAPHIC**

**DISTRIBUTION: ELBOWS, KNEES, SCALP**





# PHYSICAL EXAMINATION

**PATTERN RECOGNITION**

**LICHEN STRIATUS**

**TYPE OF LESION:**

**MODIFIER:**

**CONFIGURATION:**

**DISTRIBUTION:**

